



# Combined meniscectomy and repair? Case-based

G DEMEY

Lyon Ortho Clinic – Clinique de la Sauvegarde  
Lyon France

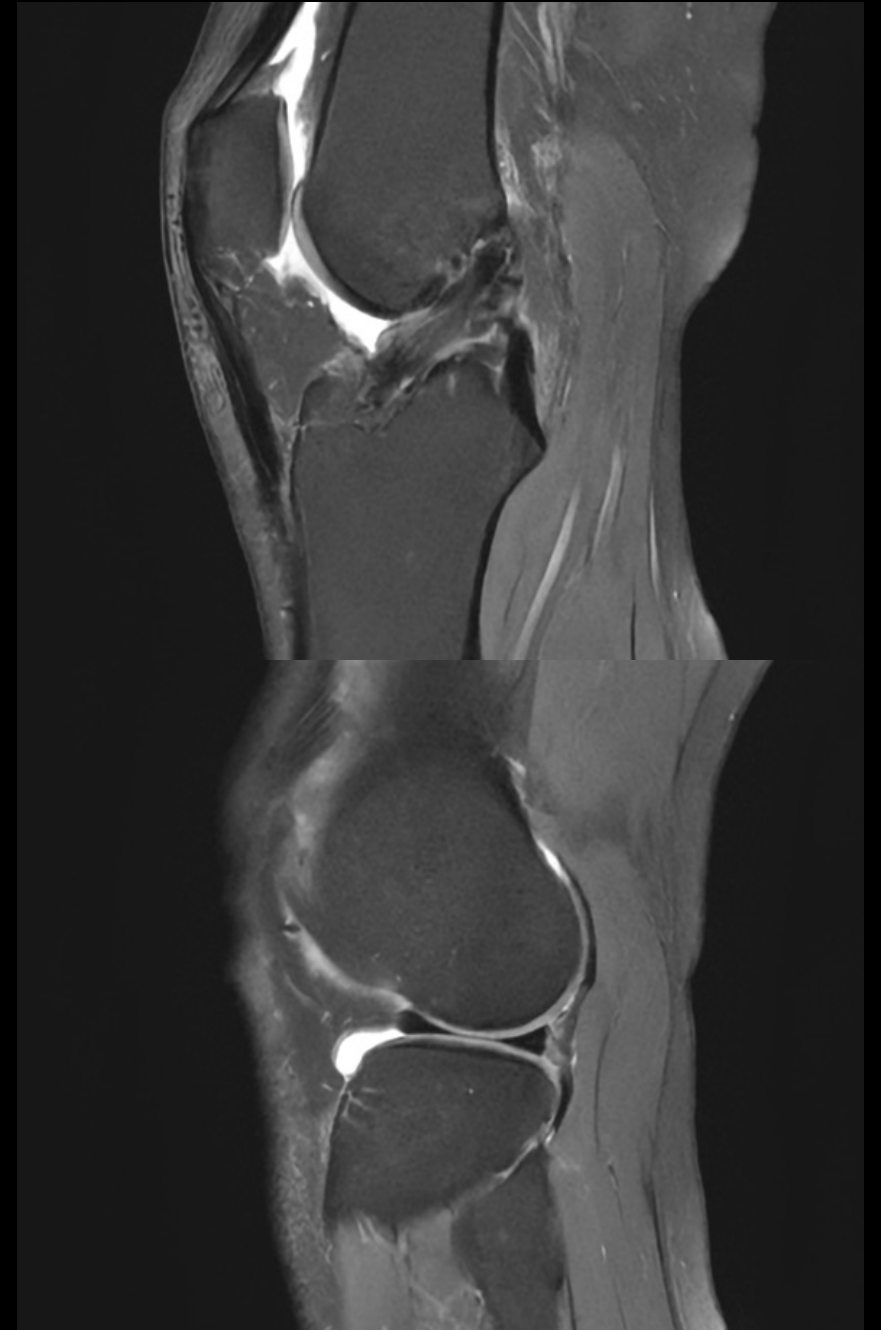

LYON **ORTHO** CLINIC



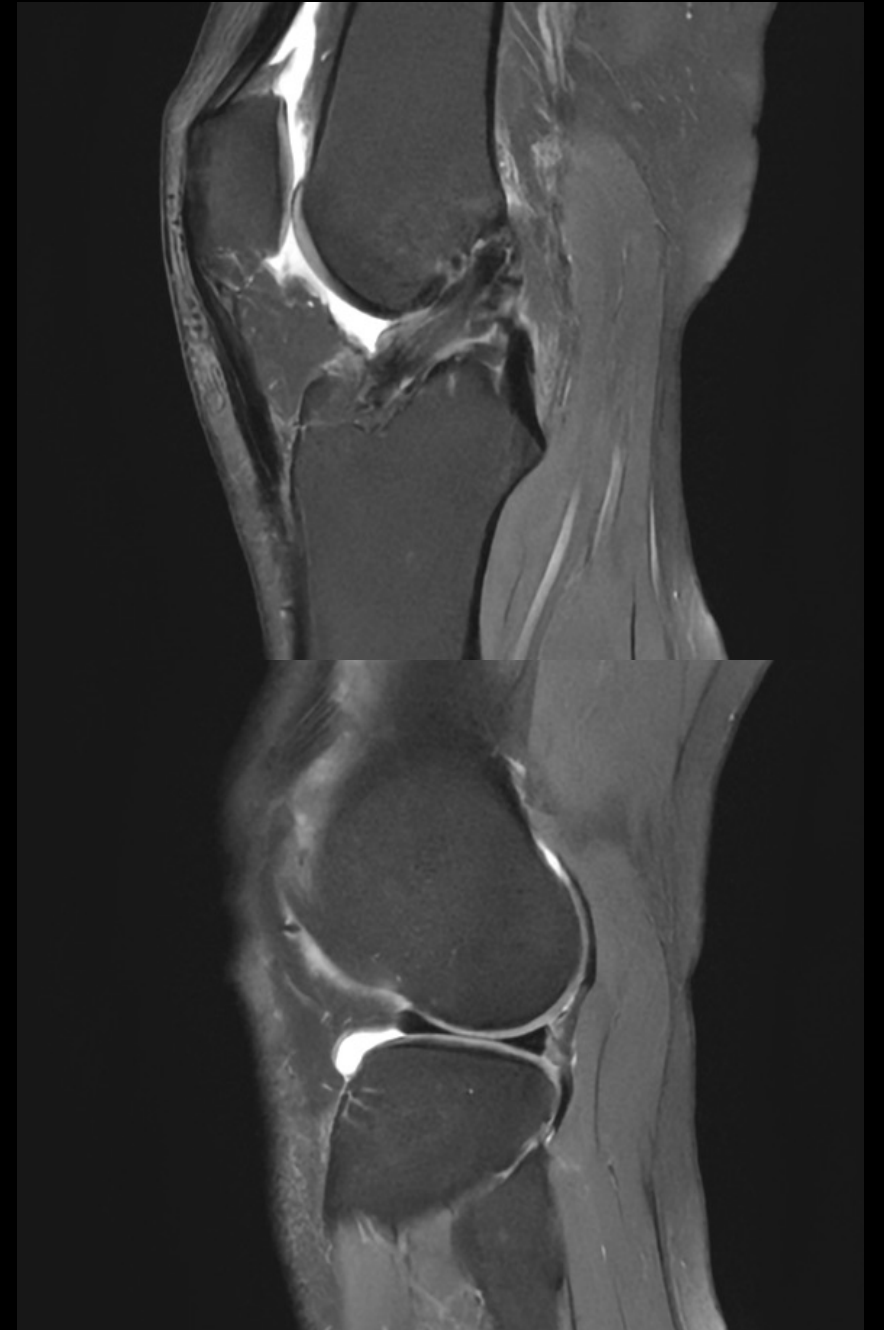# Case 1

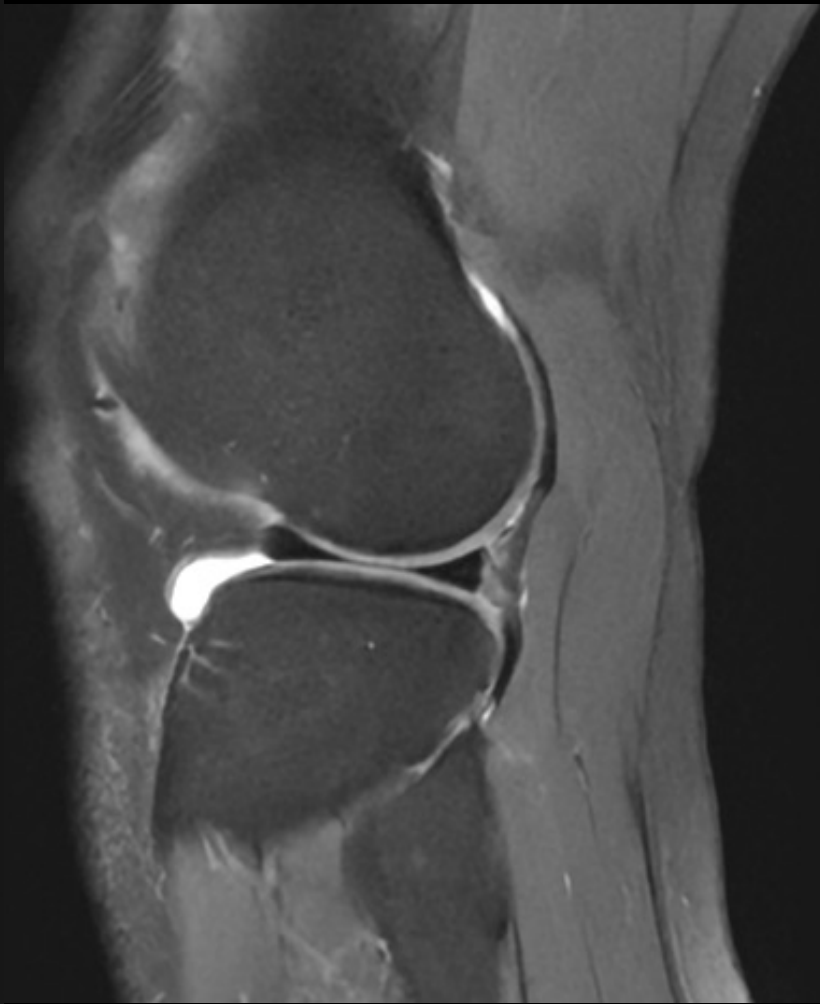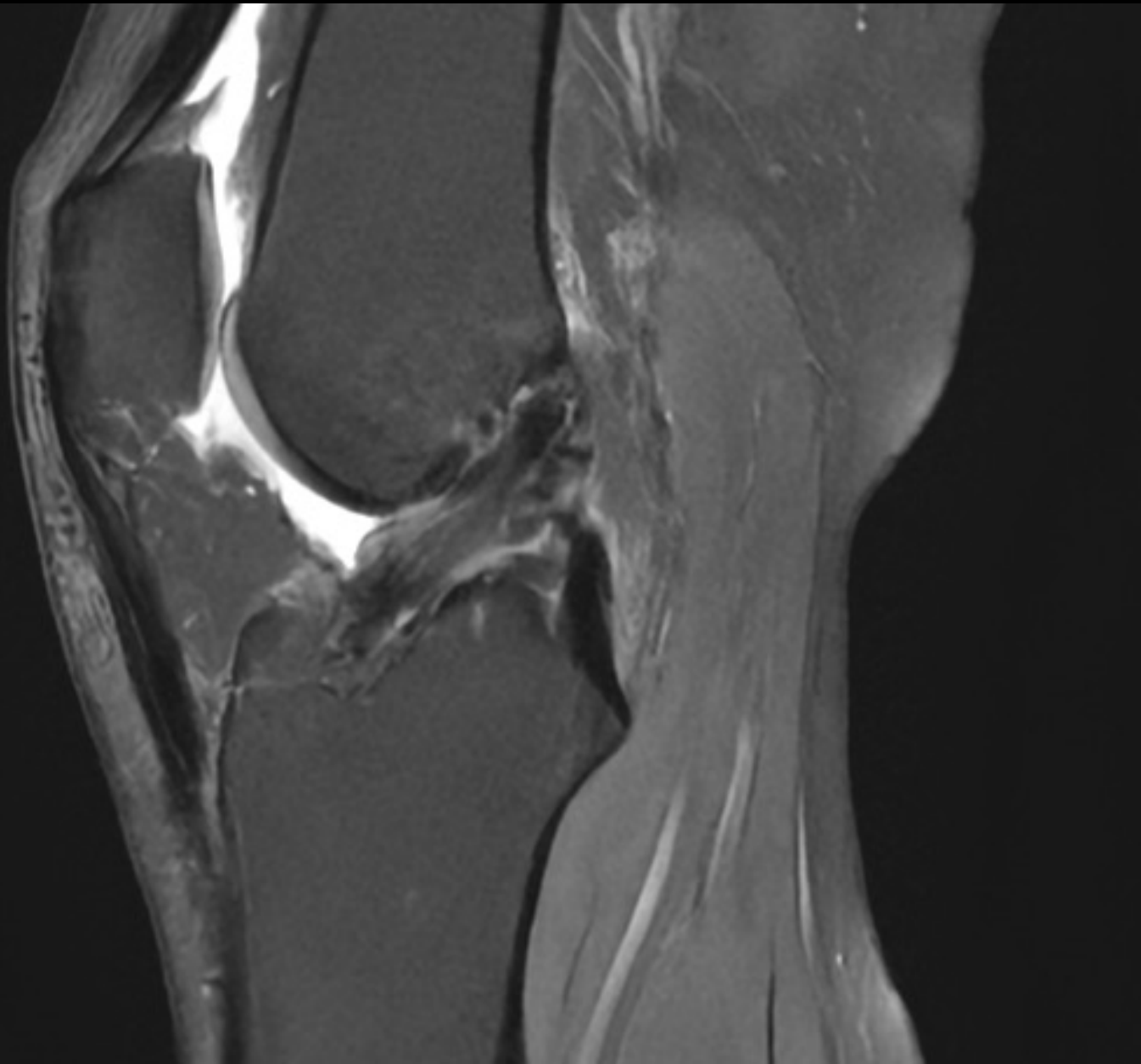
- 35yo Female
- ACLr + MM repair on 2015
- Cyclops syndrom treated under scopy
- After a knee torsion, she felt pain and a clunck
- Sport activities : cross-fit, cycling, Running
- BMI = 23 (1m67 / 65Kg)

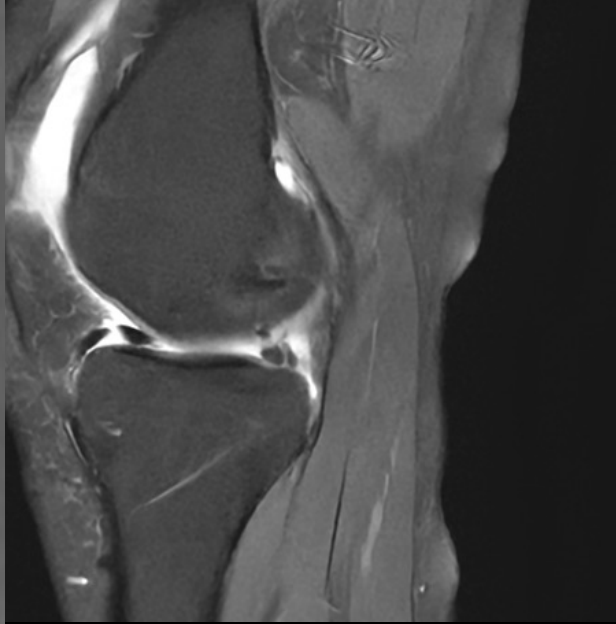
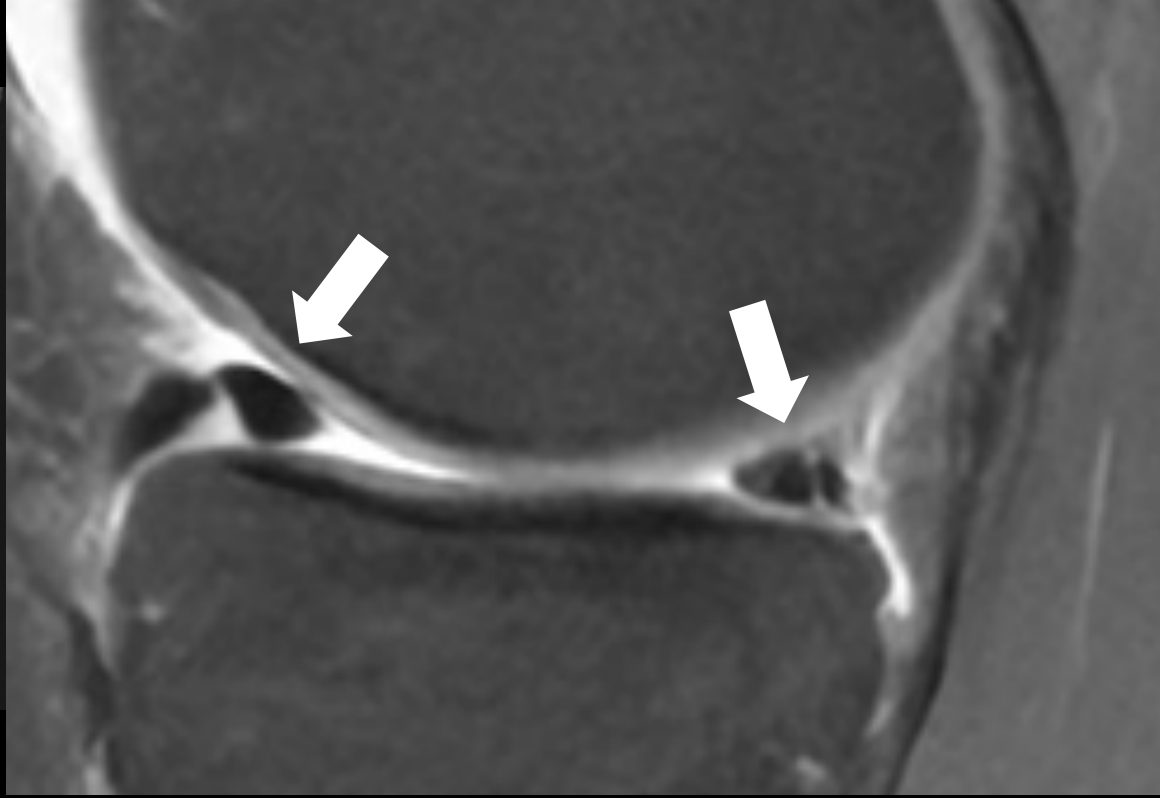
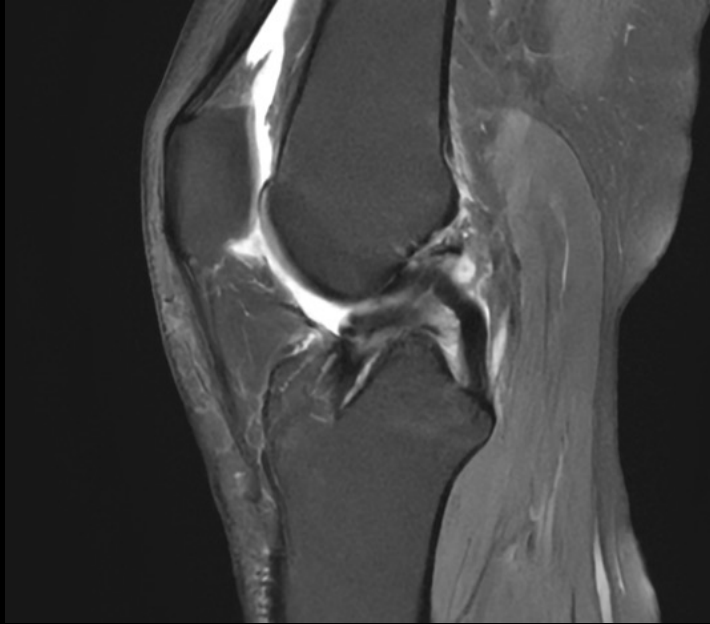


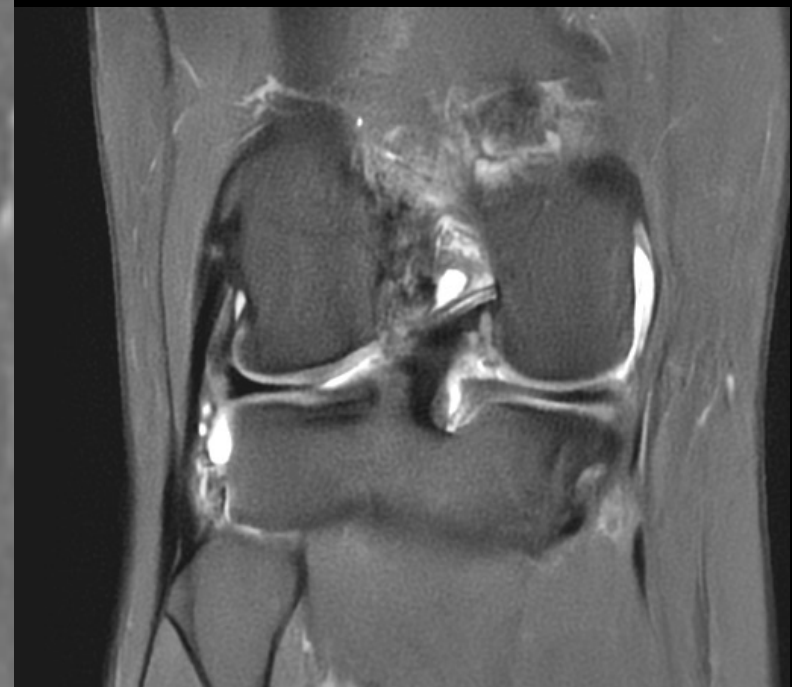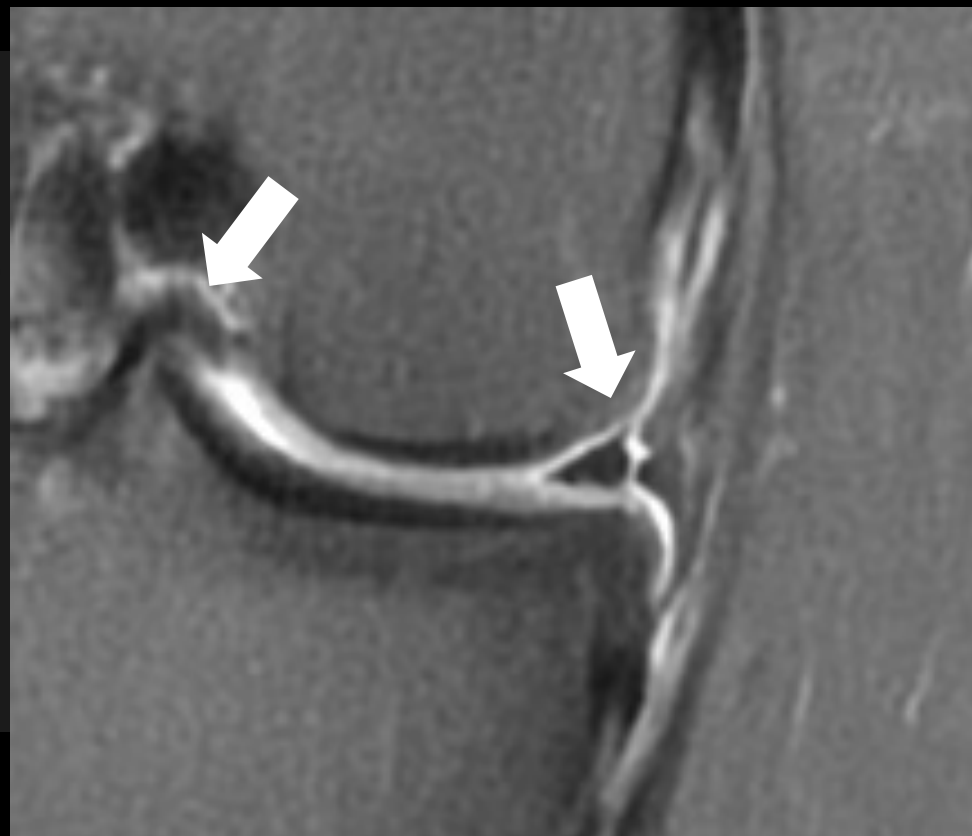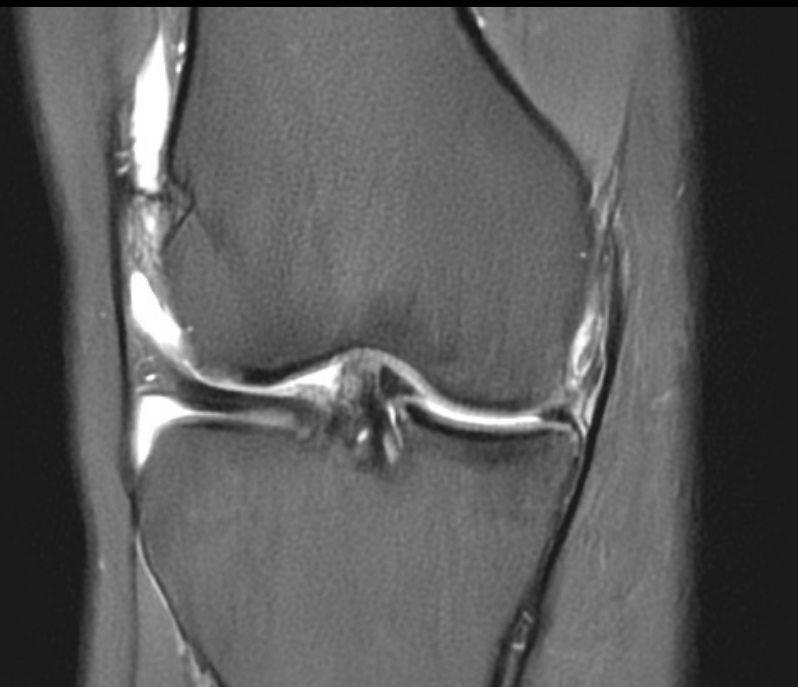## Clinically

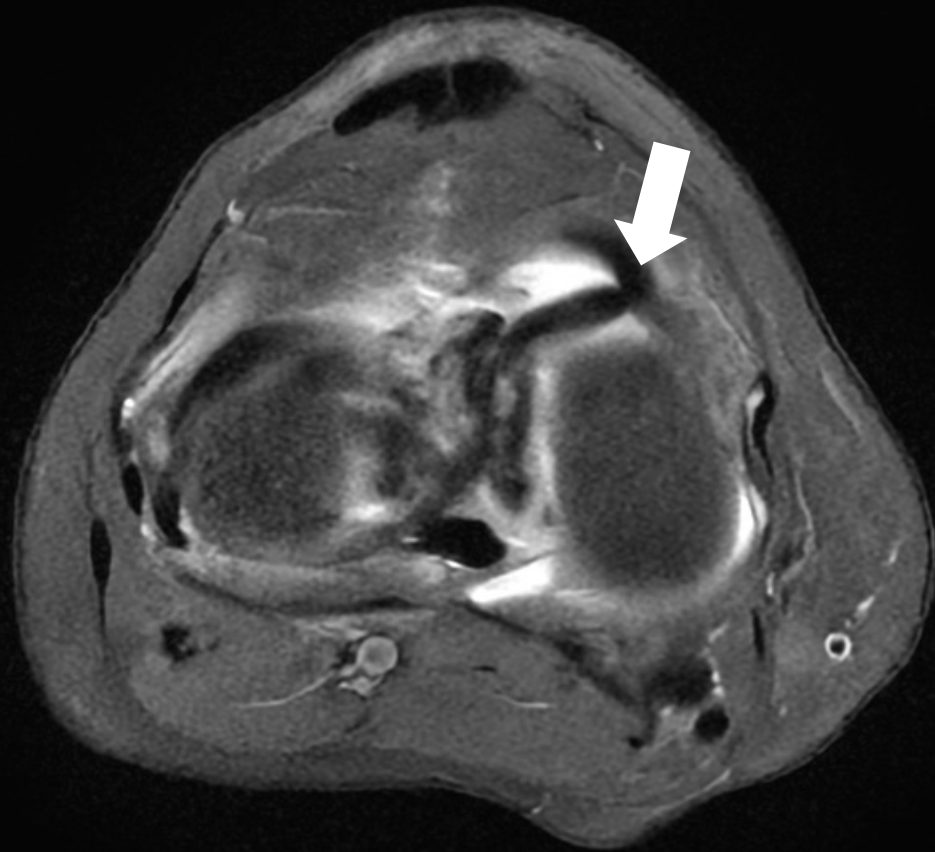
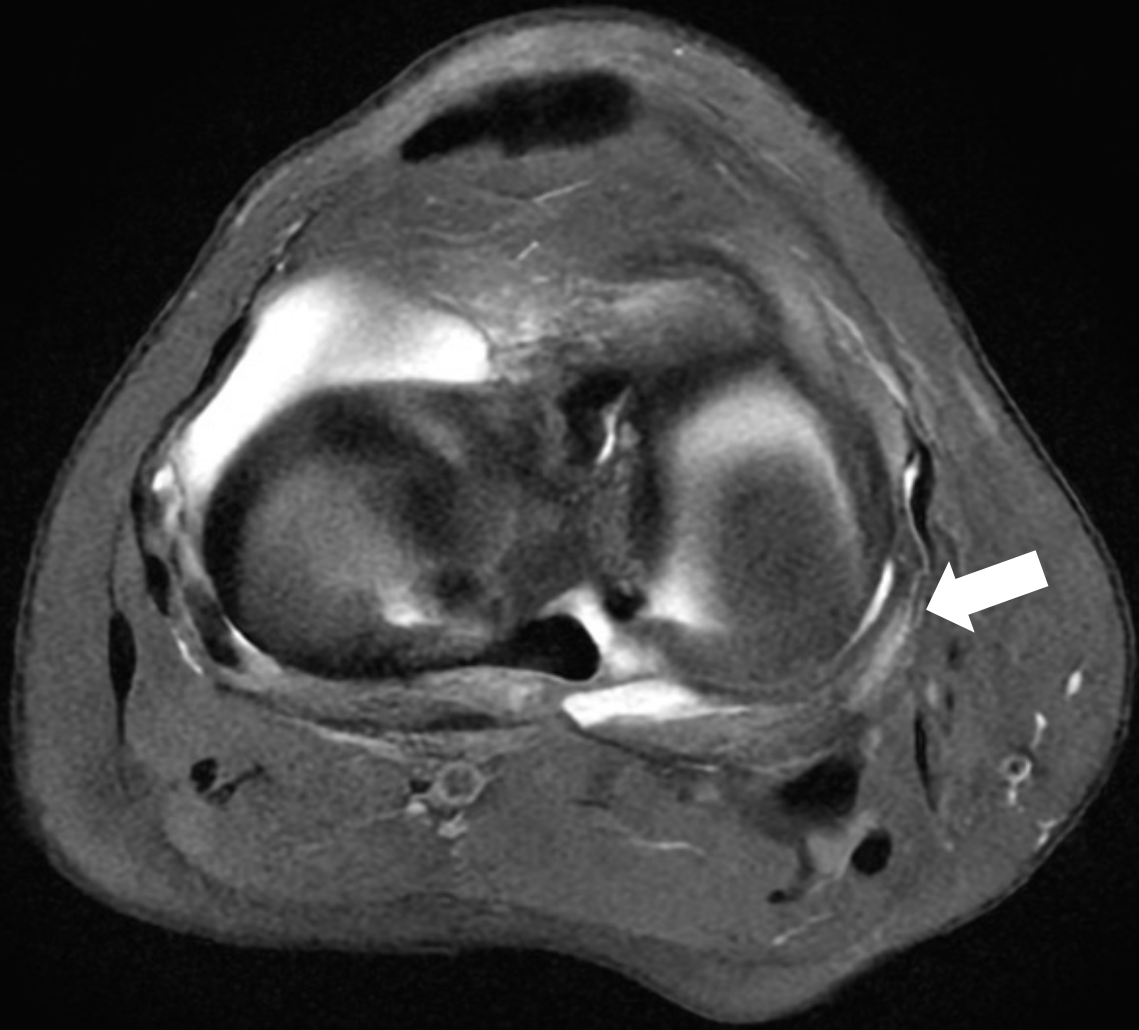
- Effusion
- Medial joint line tenderness
- Normal ROM (0/0/140)
- Lachman test : hard endpoint
- Negative pivot shift test

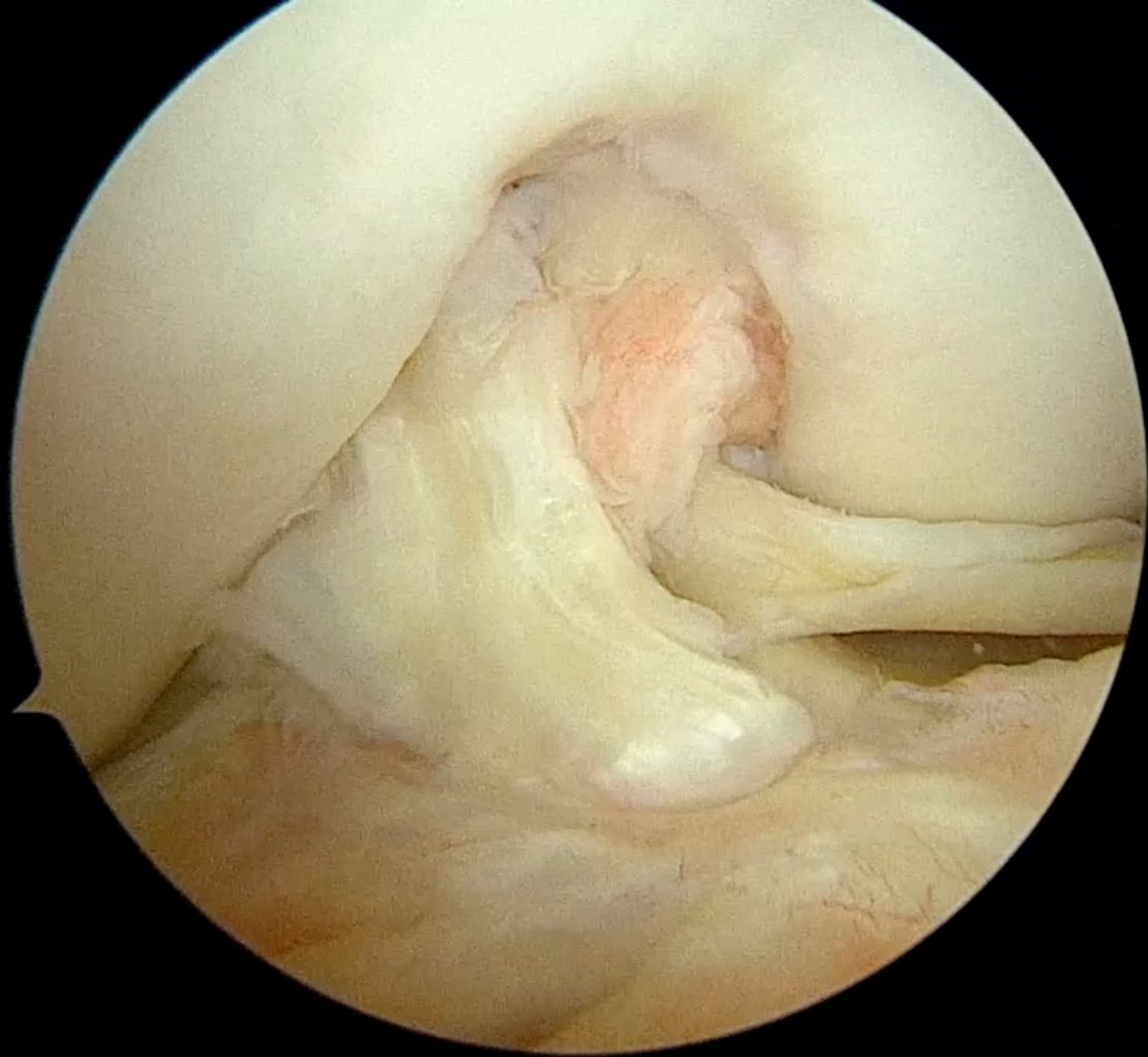




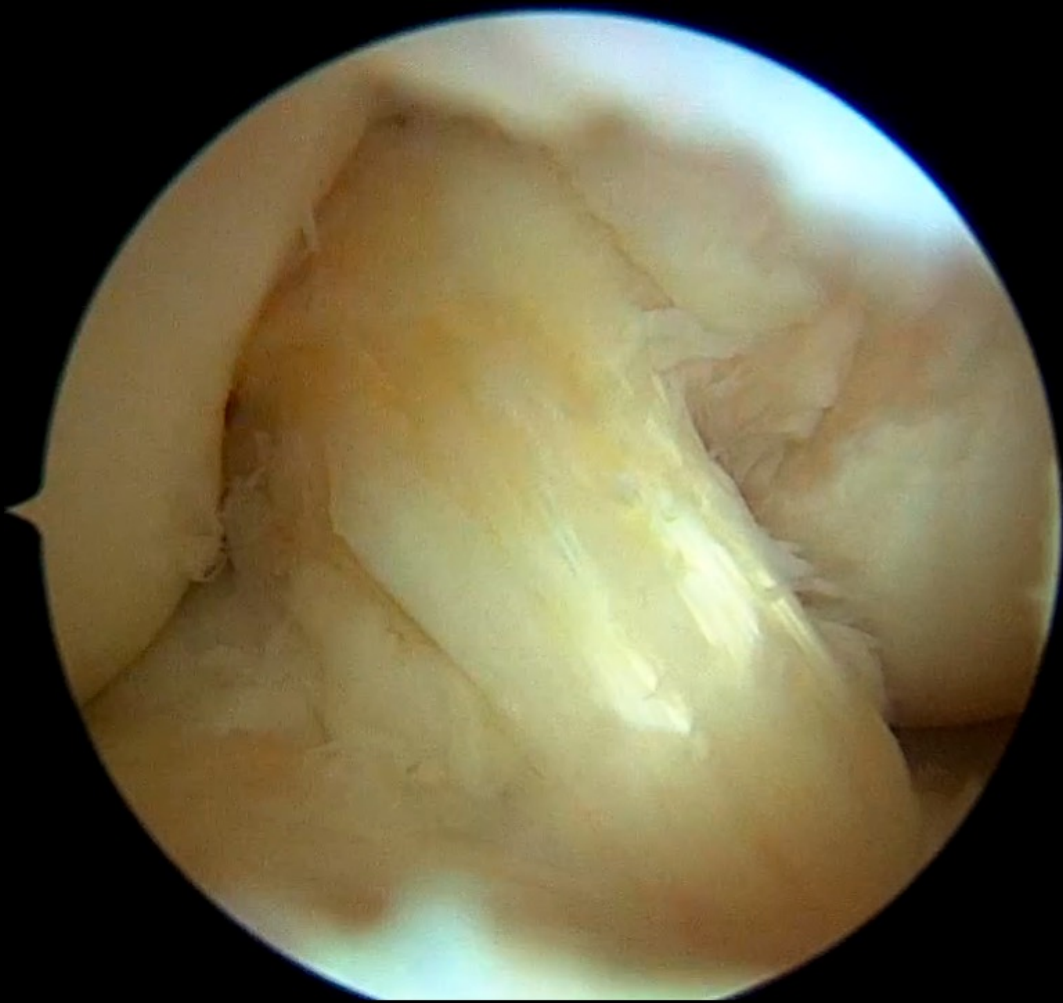
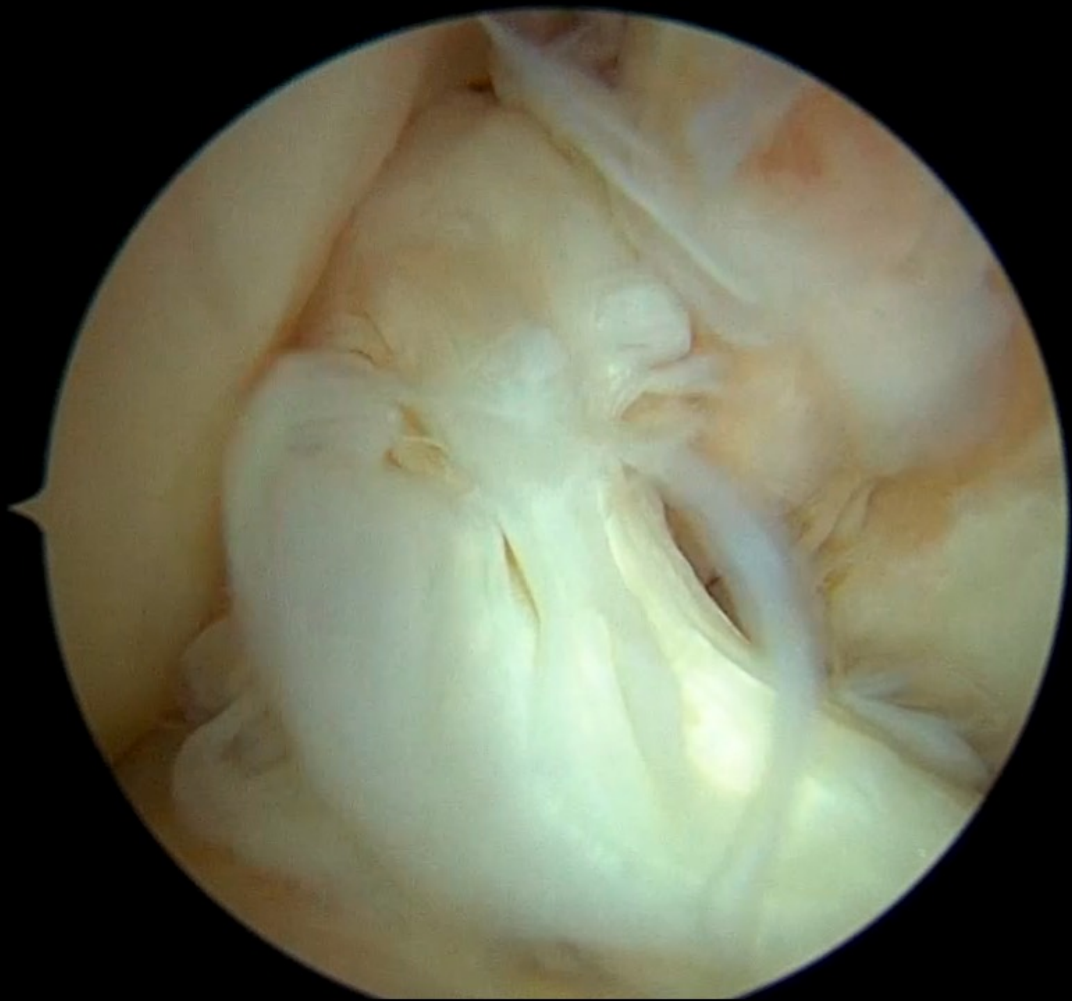


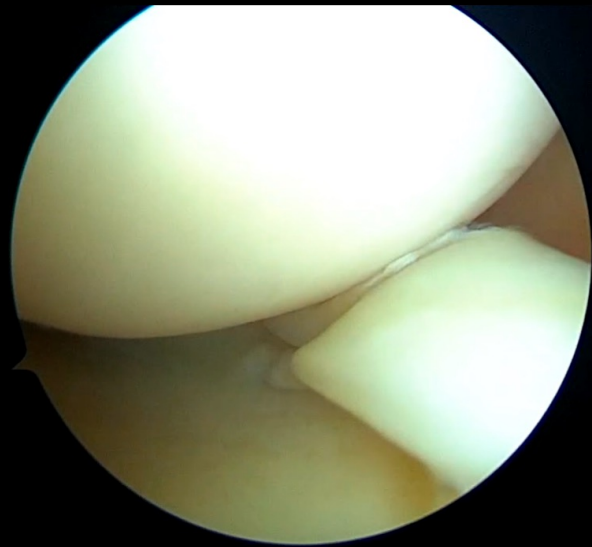




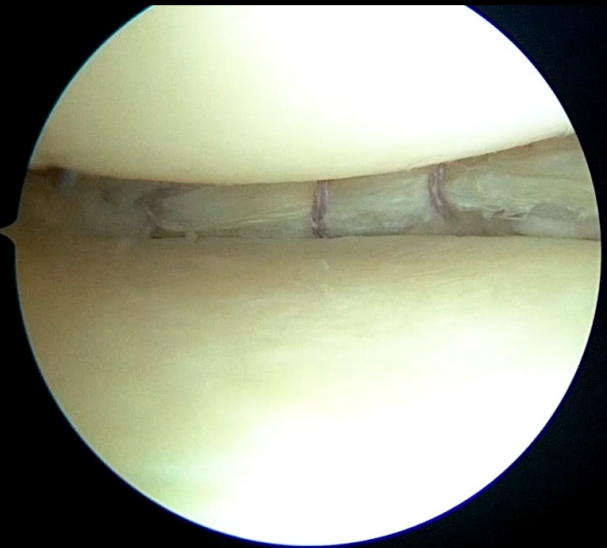
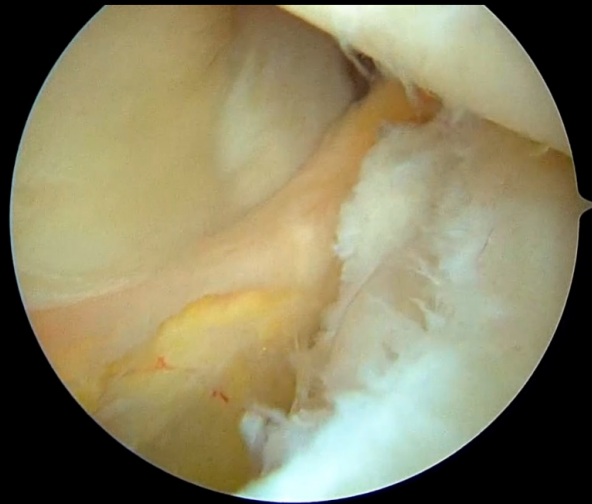




**BH tear**

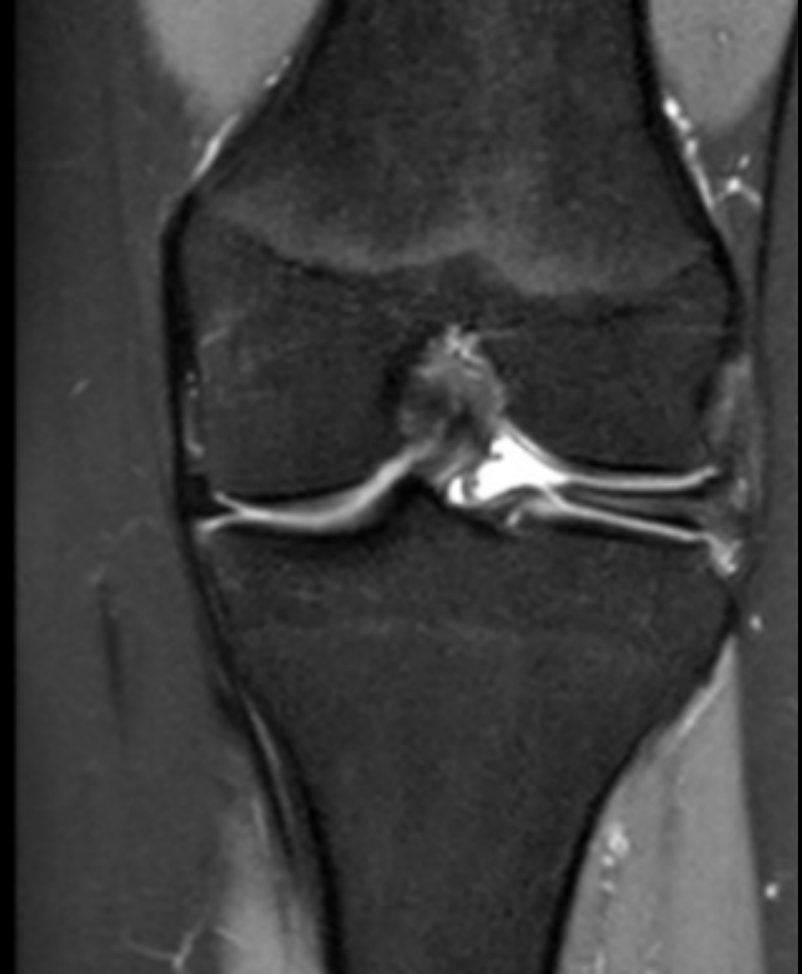


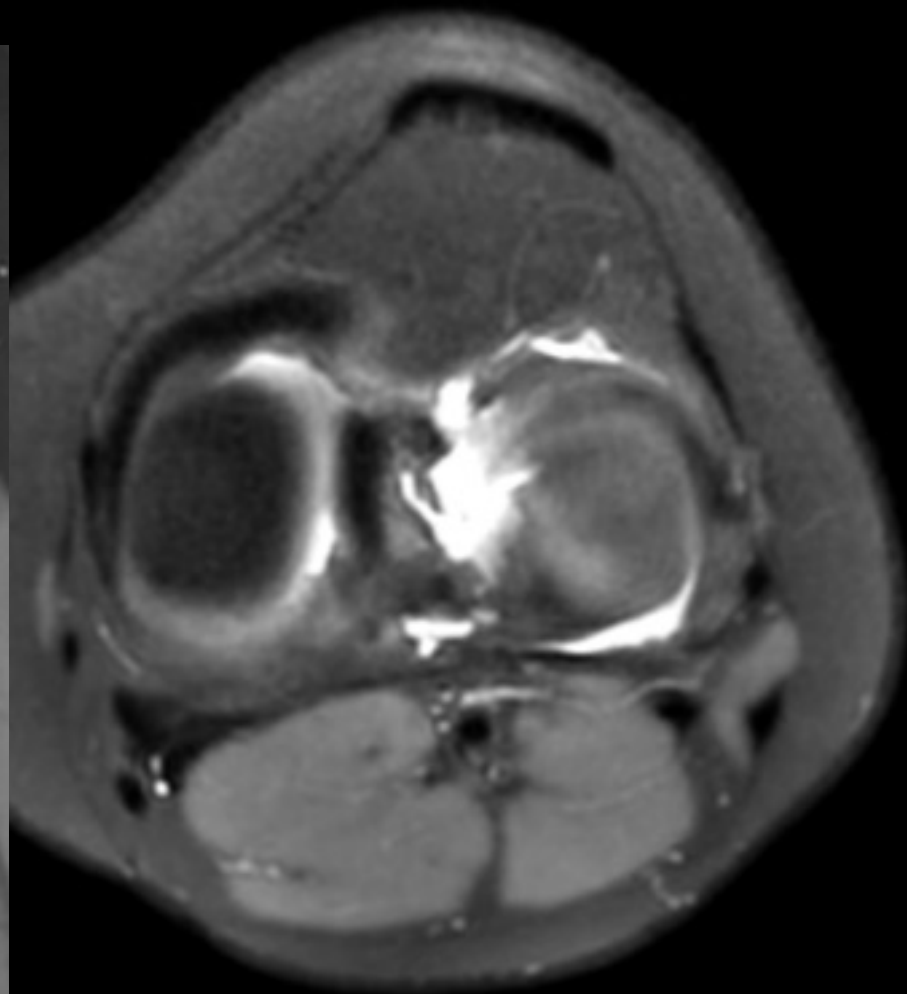
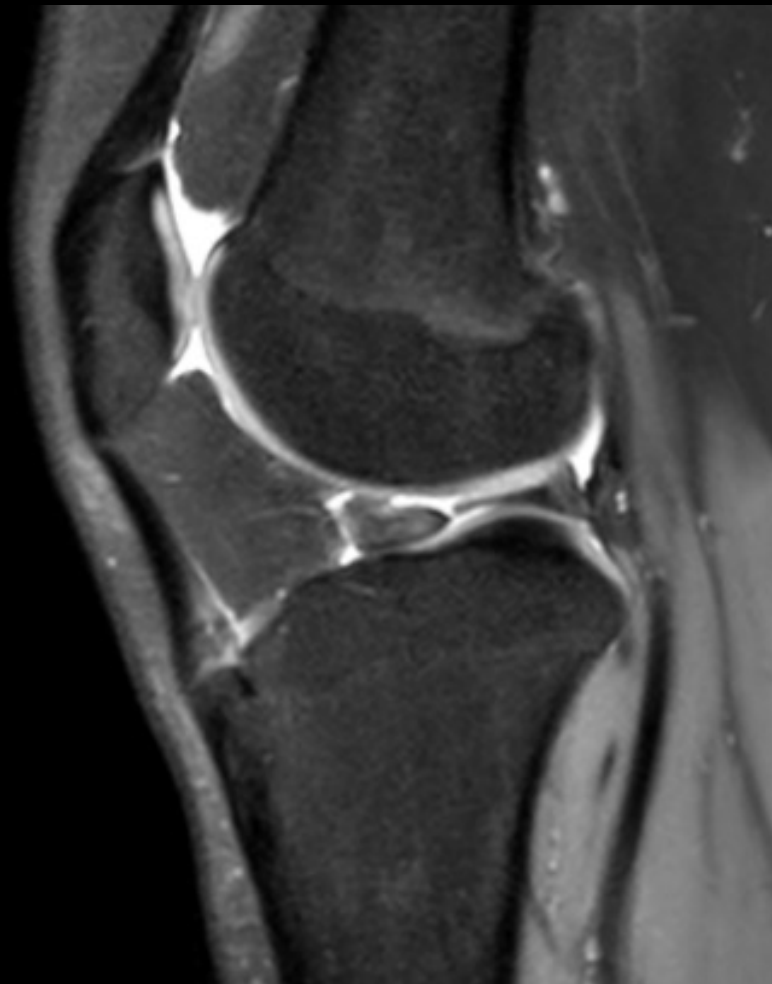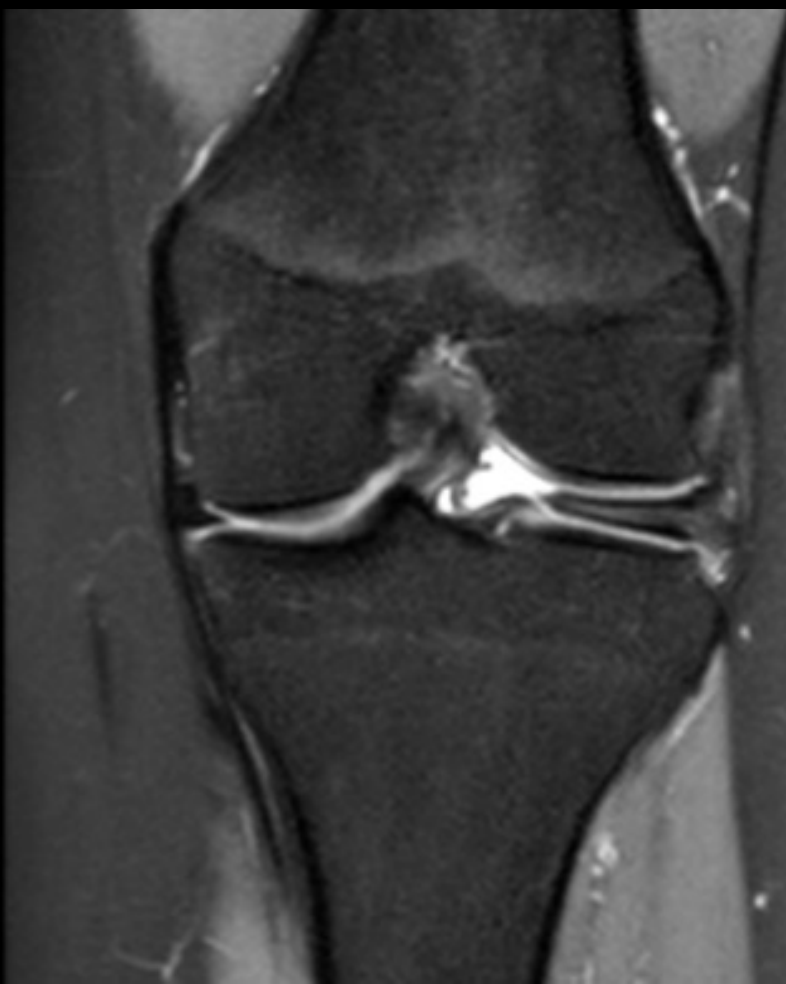**RAMP lesion**

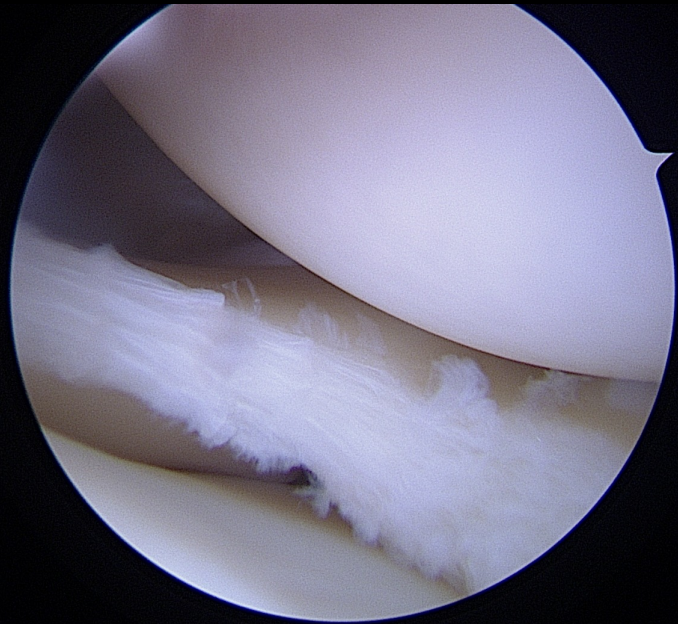
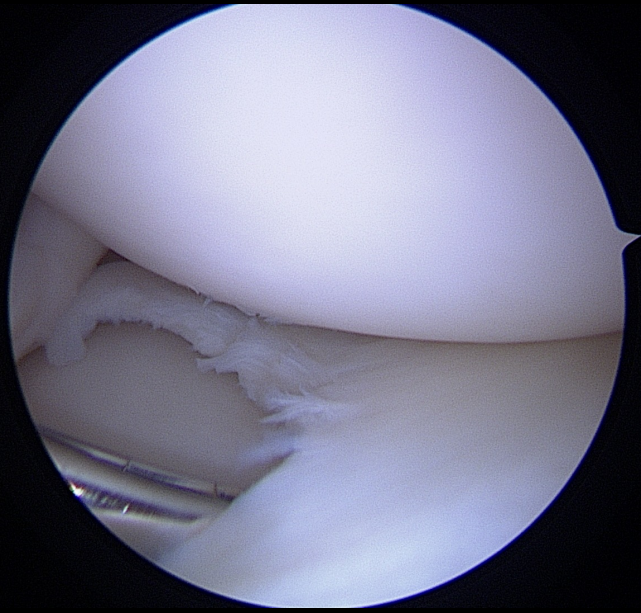


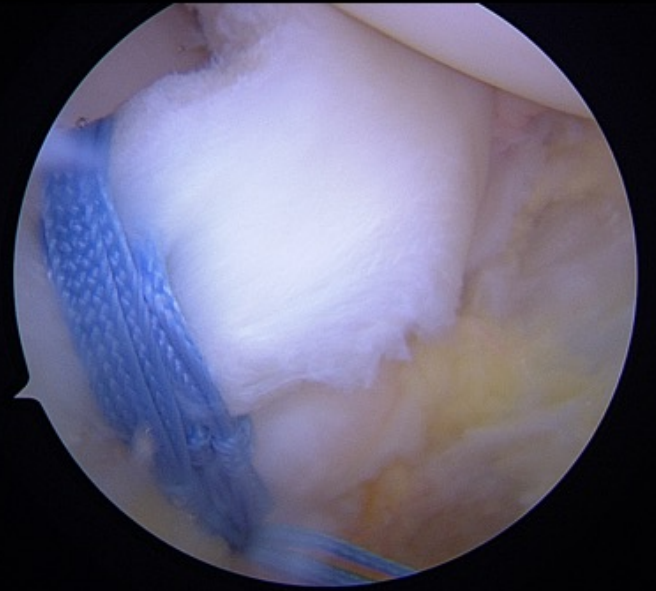
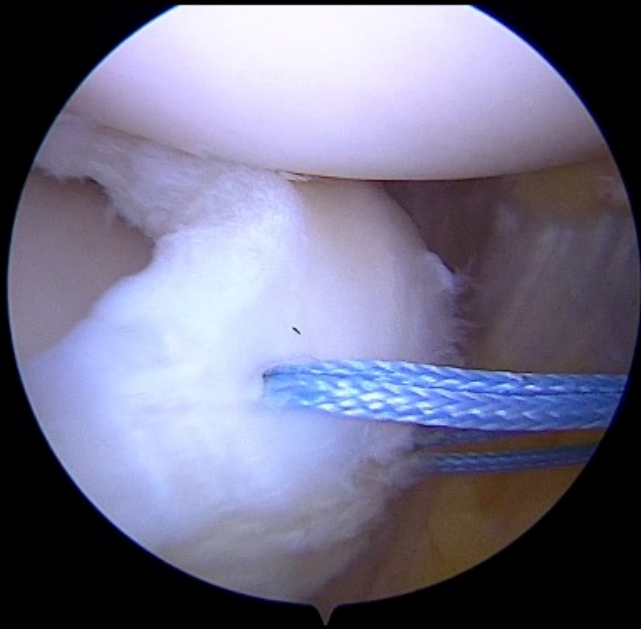
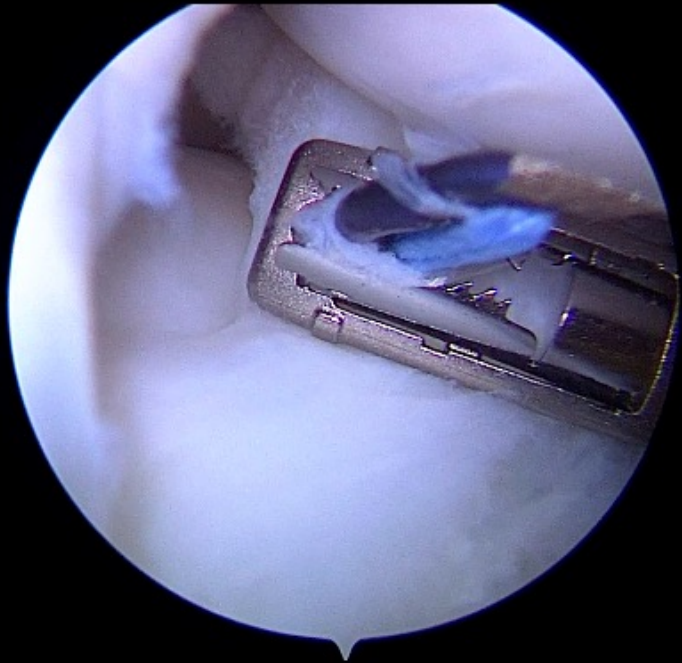
## Case 2

- 15yo Girl
- Pain for the past year
- Lateral clunck
- Normal ROM (0/0/140)
- Lachman test : hard endpoint
- Negative pivot shift test
- Genu valgum deformity









- Discoid lateral meniscus
- Meniscopectomy or saucerisation-suture

> [Knee Surg Sports Traumatol Arthrosc.](#) 2023 Nov;31(11):4816-4823.

doi: [10.1007/s00167-023-07538-1](#). Epub 2023 Sep 2.

## Discoid lateral meniscus instability in children: part II.: Repair first to minimise the saucerisation

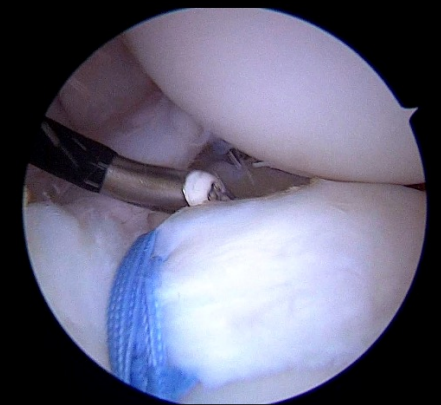
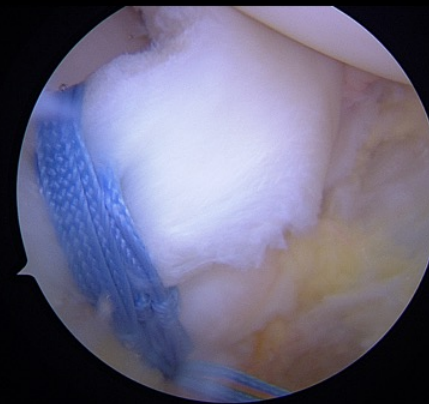
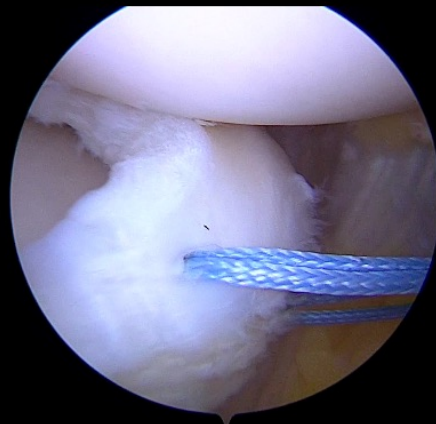
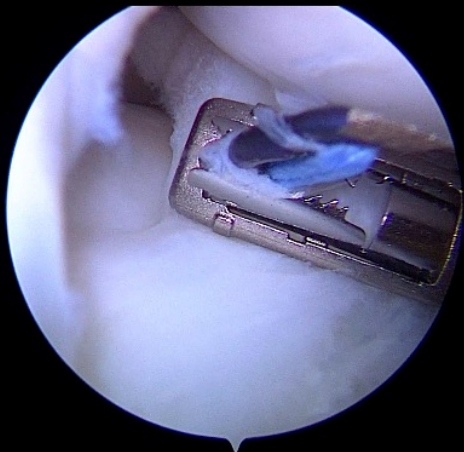
Paul Henri Bauwens <sup>1</sup>, Simon Vandergugten <sup>2</sup>, Charles Fiquet <sup>3</sup>, Sébastien Raux <sup>1</sup>, Nicolas Cance <sup>1</sup>, Franck Chotel <sup>4</sup>

Affiliations + expand

PMID: 37659011 DOI: [10.1007/s00167-023-07538-1](#)

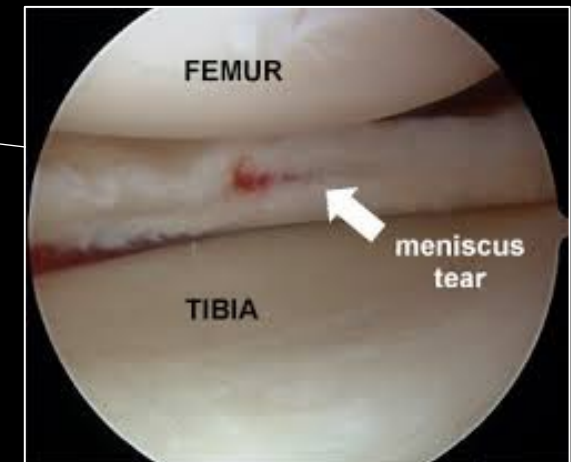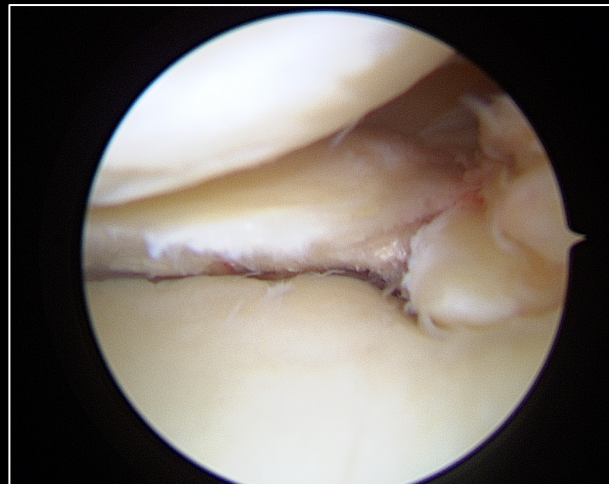Repair and fixation first

Partial  
Meniscectomy



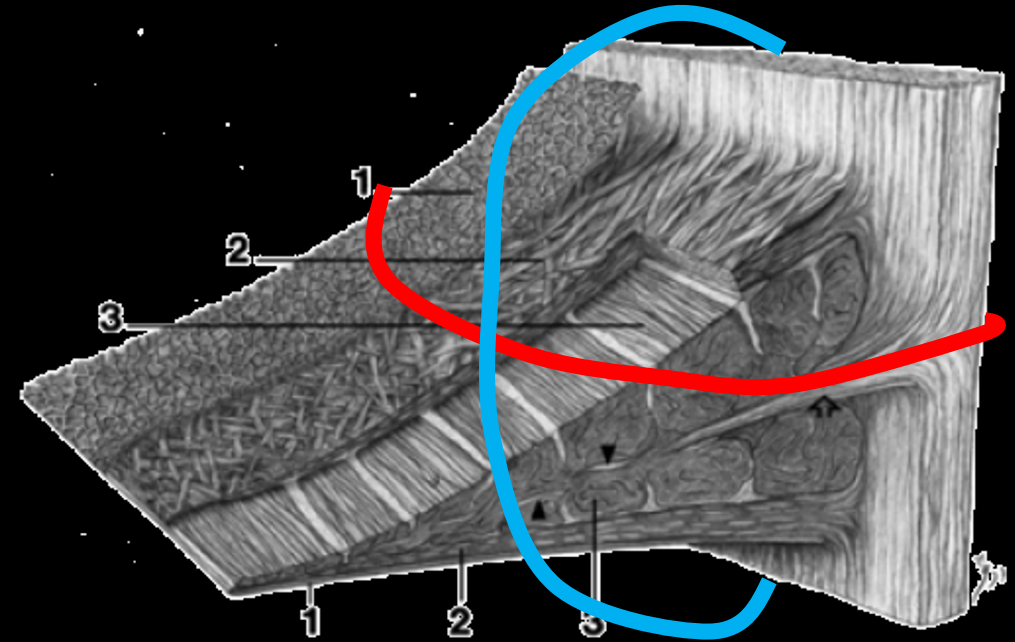
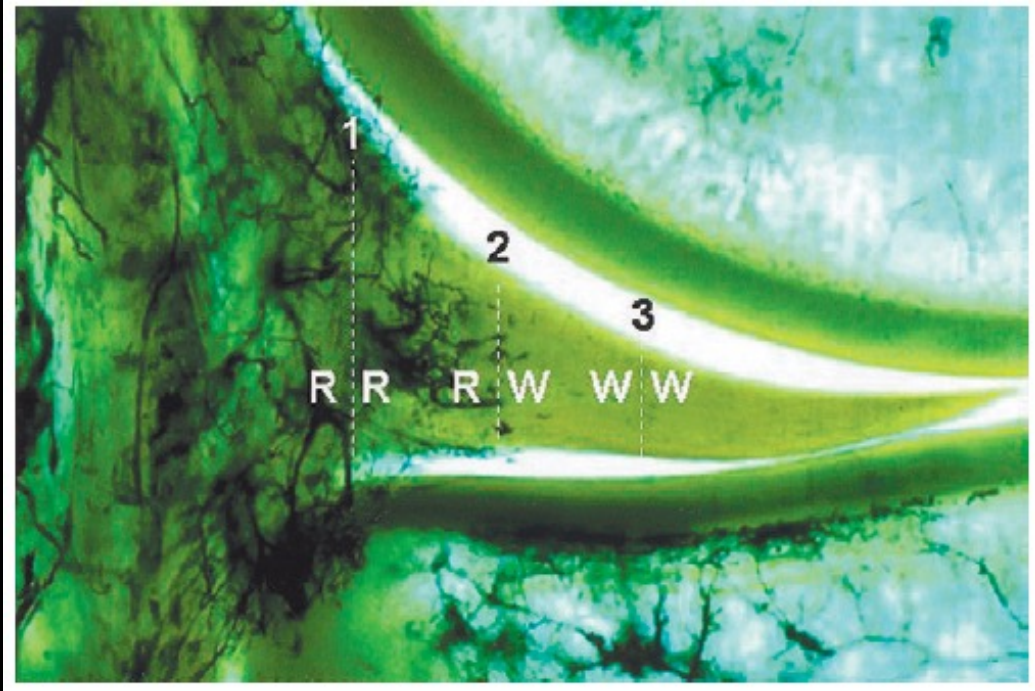# Indication

- Medial or Lateral meniscus
- Double lesions (indications determined on a case-by-case basis)
- Discoïd Meniscus
- Horizontal cleavage
- Degenerative Root Lesion



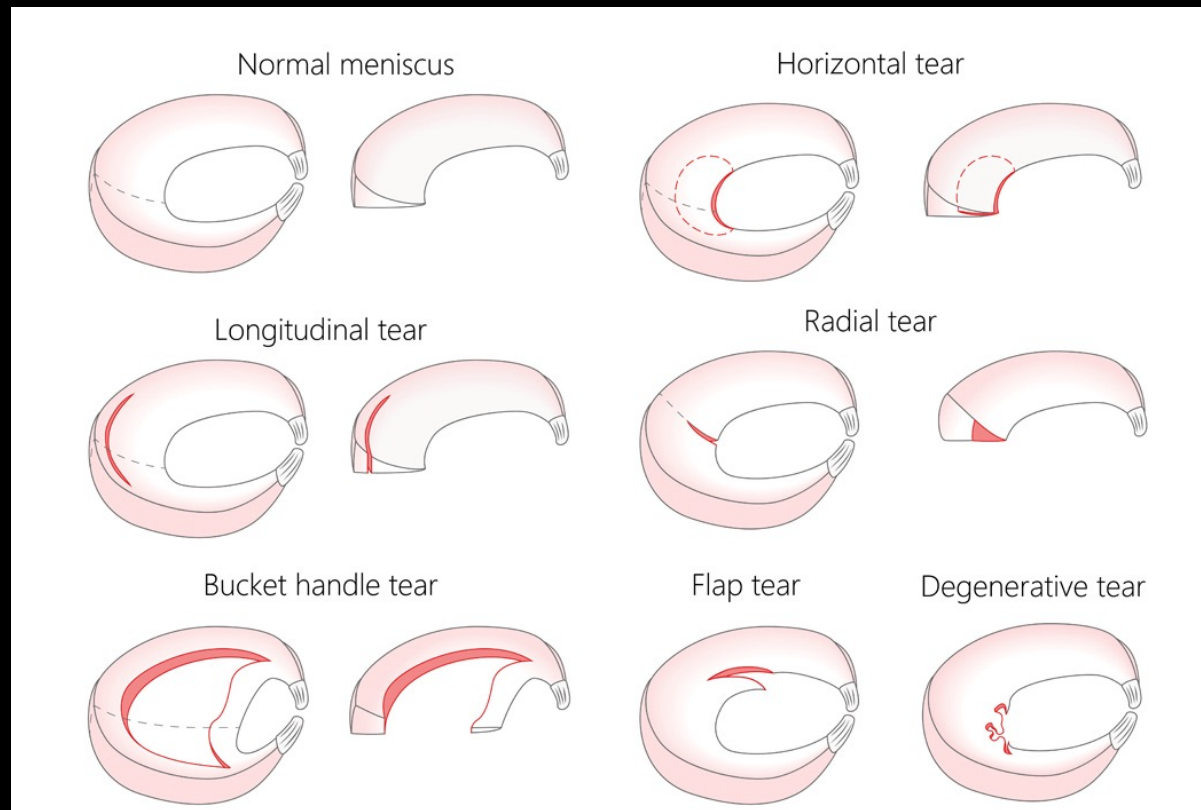


# Meniscal zone



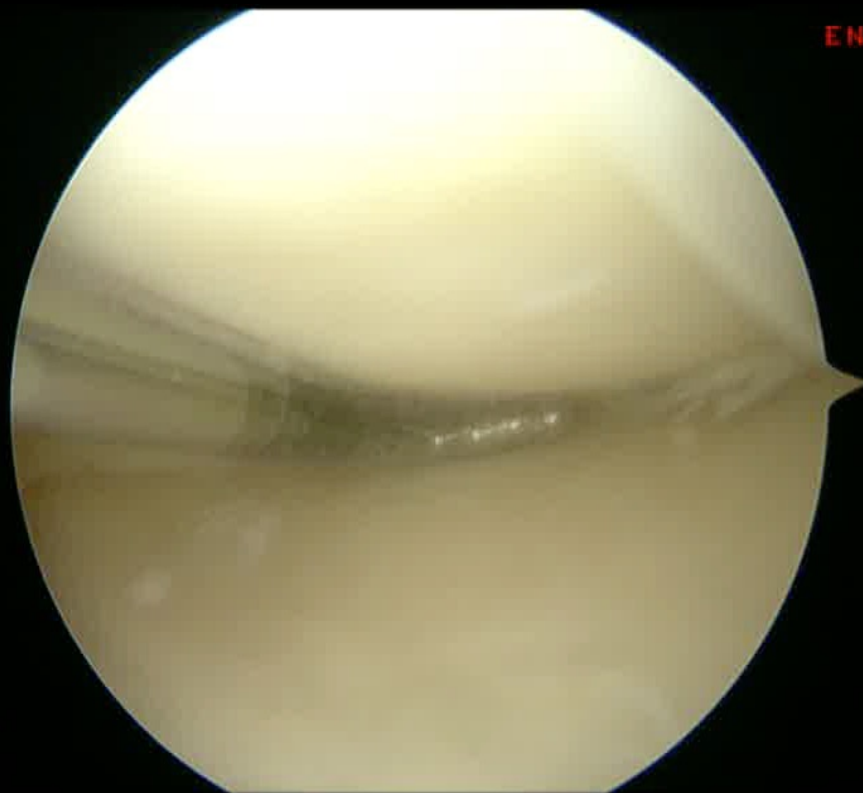
- 3 Zones
- Red/Red- Red/White- White/White

# Type of lesion

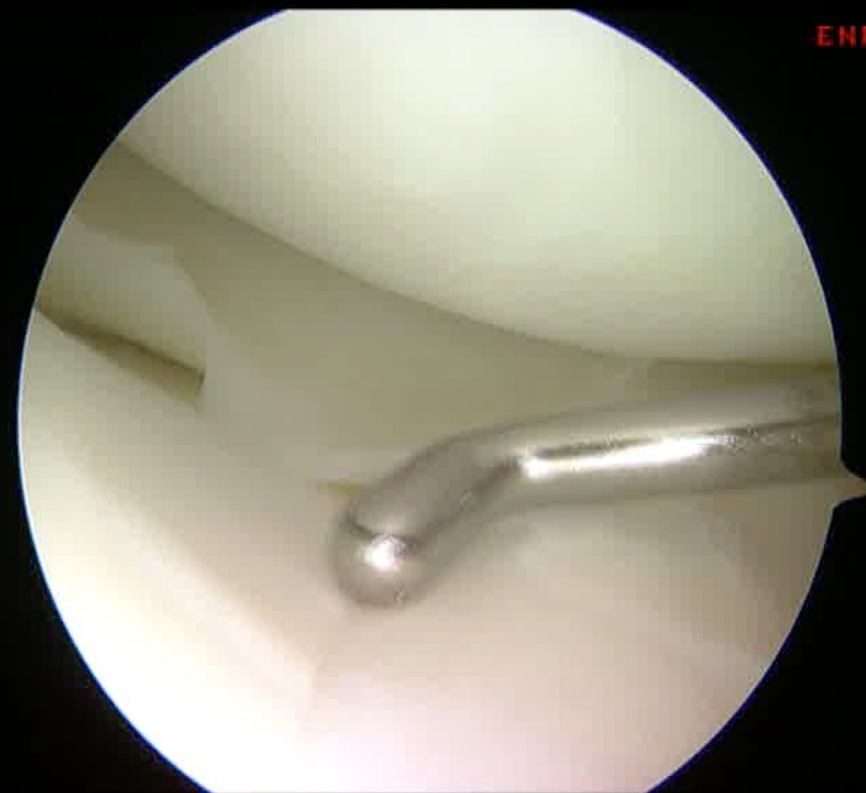

# Type of lesion

## Degenerative



## Traumatic

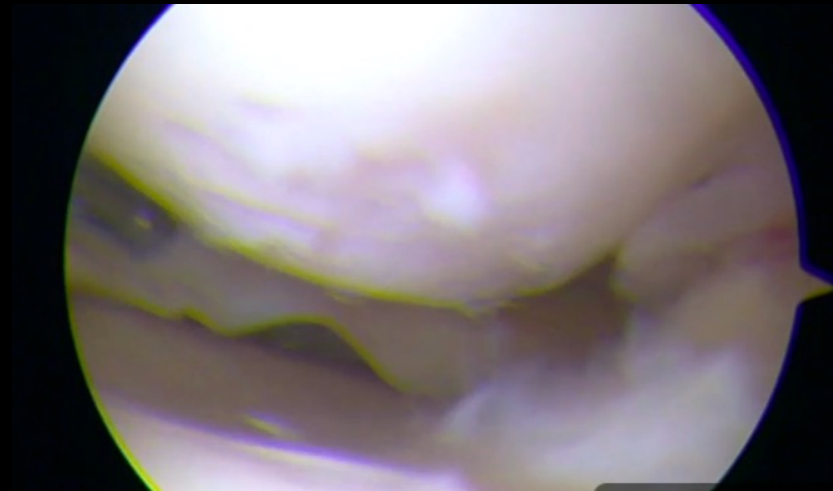

Patient

Patient



Cartilage status



# Combined partial meniscectomy + repair

- Very common
- Better than extensive meniscectomy
- Better than repairing a « non-repairable » lesion (compromise?)
- Indications are determined on a case-by-case basis



LYON **ORTHO** CLINIC

